Combining Optical Coherence Tomography (OCT) with an operating microscope

Eva Lankenau[1], David Klinger[1], Christian Winter[1], Asim Malik[1], Heike Hedwig Müller[2], Stefan Oelckers[2], Hans-Wilhelm Pau[3], Timo Just[3], and Gereon Hüttmann[1]

[1] Institute of Biomedical Optics, University of Lübeck, Germany
E-mail: huettmann@mll.mu-luebeck.de
[2] Möller-Wedel GmbH, Wedel, Germany
E-mail: s.oelckers@moeller-wedel.com
[3] ENT-Department, Medical School, University of Rostock, Germany
E-mail: hans-wilhelm.pau@med.uni-rostock.de

Abstract. Optical coherence tomography (OCT) is an emerging biomedical imaging technology which gives high-resolution sectional images of light scattering tissue down to a depth of a few millimeter. The objective of this work is to combine OCT with an operation microscope. A spectral domain OCT was adapted via a specially designed scanning optics to the camera port of an operation microscope. This enables a non-contact on-line OCT during different medical applications. Hidden tissue structures were visualized with a resolution below 30 µm. As a first example for an application in otolaryngology we demonstrated that the OCT operation microscope is basically able to reveal parts of the cochlear morphology without opening its enveloping membranes. Thus it may serve as a helpful guide for the surgeon to exactly localize the scala tympani before opening the fluid-filled inner ear for inserting the electrode array of cochlear implants.

1. Introduction

Optical coherence tomography (OCT) [1] is an emerging biomedical imaging technology that has been applied to a wide range of biological, medical, and material investigations. Similar to B-mode ultrasound imaging, reflections of near-infrared light are detected, which offers a non-contact real-time in vivo imaging of solid tissues. Depending on the scattering characteristics tissue structures 0.5 to 1.5 mm below tissue surface can be seen. Typically, a spatial resolution of 6-15µm is obtained. Recent developments in retinal imaging have demonstrated a resolution of 3 µm permitting the differentiation of individual retinal layers in vivo [2]. First medical applications of OCT were found in ophthalmology where imaging can be performed on transparent media of the anterior eye and the retina [3,4,5]. OCT using optical sources at longer wavelengths has enabled imaging in highly scattering soft tissues, which now includes applications to cardiology [6], gastroenterology [7,8], urology [9,10], dermatology [11,12], dentistry [13], and the central nervous system [14,15,16]. There are different developments to perform OCT measurements through an

In: Buzug TM, Holz D, Weber S, Bongartz J, Kohl-Bareis M, Hartmann U (eds) Advances in Medical Engineering. Springer, Berlin, Heidelberg, pp 343-348, 2007

colposcope [17], fiber-optic catheters and endoscopes [18, 19], and hand-held probes [12].

Here, we describe the combination of spectral domain optical coherence tomography (SD-OCT) with an operation microscope, which promises new medical applications for OCT.

2. Experimental Methods

SD-OCT is a coherent imaging method. Infrared light with a short coherence length is split by an interferometer into two parts, a probe and a reference light, which are either directed to the tissue or to a reference mirror, respectively. The light collected form the sample and the reference light are superposed at the output of the interferometer. The modulation of the cross correlation spectrum contains the distances of the light scattering structures in the tissue with respect to the reference distance. A Fourier transform of the measured spectra reveals the OCT A-scan of the depths resolved backscattering intensity. OCT B-scans are produced by scanning the probe in lateral direction and converting the A-scan amplitudes to logarithmic gray scales [21].



Fig. 1. OCT operating microscope with a working distance (WD) of about 250 mm : a) spectral domain OCT device, b) PC with Labview software, c) OCT adapter, d) OP-microscope.

A spectral domain optical coherence tomography (SD-OCT) device which was developed at the Institute of Biomedical Optics, University of Luebeck, and manufactured by the Thorlabs HL AG (Luebeck, Germany), was coupled to the camera port of an OP-microscope (HiRes1000, Möller-Wedel, Wedel, Germany), thereby using the same optics for OCT and conventional imaging (Fig.1). The scan range changed as the field of view was altered and the OCT system could adapt for changes of the working distance in the range from 232 mm to 290 mm by a motor control of reference mirror. A one axis scanner was implemented in the adapting optics which gives horizontal OCT section of the tissue in the center of imaging field.

The SD-OCT system consisted of a superluminescence diode at a central wavelenth of 840 nm and achieved an axial resolution of 11 µm in air. SD-OCT in the configuration used here produced a B-scan image with 3,6 mm imaging depth. The data were acquired at a rate of 1220 A-scans/second, digitized with 16 bits resolution, and transformed to A-scans on-line on the host computer. Data acquisition software was written in Labview.

3. Results and Discussion

For easily locating areas of interest overview images are necessary. For a high quality OCT images a high magnification is advised. The build-in zoom function of the HiRes1000 allowed to change the image magnification by a factor of six. Correspondingly the scan range changed from 4 mm to 24 mm. Figure 2 shows the image of a finger nail with two different imaging fields at a working distance of 232 mm.



Fig. 2. Image of finger nail together with adjacent skin with the OCT operation microscope at a) lowest and. b) highest magnification.

The lateral resolution was nearly diffraction limited and depended on the magnification of the conventional image and the actual working distance of the microscope. Depth resolution was limited by the spectral width of the light source to 11 µm in air. In OCT images the speckle noise usually limits the resolution. The average diameter d of the speckle is essentially the diffraction limited

resolution [22], which depends on the wavelength λ and the numerical aperture NA

$$d = 0.61\frac{\lambda}{NA} \tag{1}$$

Accordingly the lateral speckle size varied from 23 µm to 47 µm for the different magnifications and working distances (Table 1). The speckle size was larger than what is usually used in OCT because of the large working distance.

Table 1. Calculated speckle sizes for different magnifications and working distances

working distance	232 mm, highest mag.	232 mm, lowest mag.	290 mm, highest mag.	290 mm, lowest mag.
lateral scan size	4 mm	24 mm	4,8 mm	28 mm
calculates speckle diameter d	23 µm	39 µm	26 µm	47 µm

Due to the binocular design the NA of an operation microscope is limited to values of 0.02 or smaller, if the normal imaging path is used. To judge the degradation of the image quality due to this limited, NA tissues were measured with different diametes of the imaging lens. Figure 3 shows OCT B-scan of an mouse brain tissue, which was acquired with $NA = 0.06$, and $NA = 0.02$. As expected, small details of the tissue structure disappear under the speckles for the lower NA images. The imaging depth was not significantly decreased, although less light was detected.

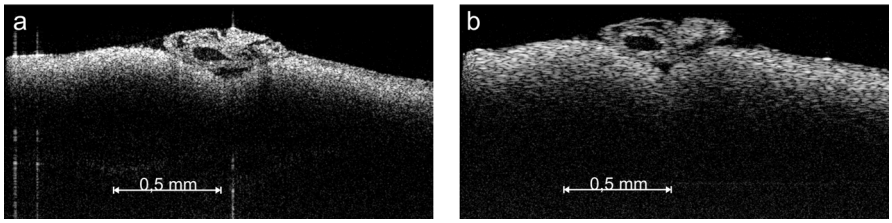

Fig. 3. Ex-vivo OCT images of mouse brain measured at nearly the same position with a numerical aperture of 0.06 (a) and 0.02(b).

An alternative approach to integrate OCT is the use the whole diameter of the front lens of the operation microscope. This would have needed significant changes in the optics or an increase of the size of the instrument which causes problems for some clinical applications. Therefore a complete integration of the OCT system into the operation microscope via the camera port was chosen though it sacrifices lateral resolution.

Speckle noise is reduced a factor of $\sqrt{N}$ by averaging images with N statistically independent speckle patterns. Imaging of the same structure under slightly varying angles causes statistically uncorrelated speckle patterns. Averaging several of these images therefore is expected to decrease speckle noise

significantly. Increases in the A-scan rate and a motor control of the different axis of the operation microscope shall make this scheme feasible in a clinical environment.

For a possible application of an OCT operation microscope during ear surgery is was tested whether the device is able to reveal parts of the cochlear morphology without opening its enveloping membranes. Fresh tissue samples were imaged after removal of the out bone of the cochlear. Through the exposed but not yet opened membranous cochlear wall (lig.spirale) adjacent inner ear structures (scala tympani, scala vestibuli) could be visualized (Fig. 4).

Thus OCT may serve as a helpful guide for the surgeon to exactly localize the scala tympani before opening the fluid-filled inner ear when inserting the electrode array of a cochlear implant. In the past there was no imperative for an exact placement of the electrodes, since they were inserted into completely deaf cochleas, which were more or less considered just a sheath for the electrodes. Though there was always the demand to insert the array into the scala tympani, in recent studies [23] Aschendorff et al. could demonstrate by rotational tomography that in many cases the electrode finally was in the “wrong” scala, without the surgeon having noticed this malposition. In recent years the indication for cochlear implantation was extended, and surgery was carried out even on patients, who still had significant residual hearing [24]. In such cases it is essential to strictly fulfilling the demand of inserting the electrode array into the “right” scala tympani. The question for a specific landmarks, which may be provided by OCT, then becomes very important.

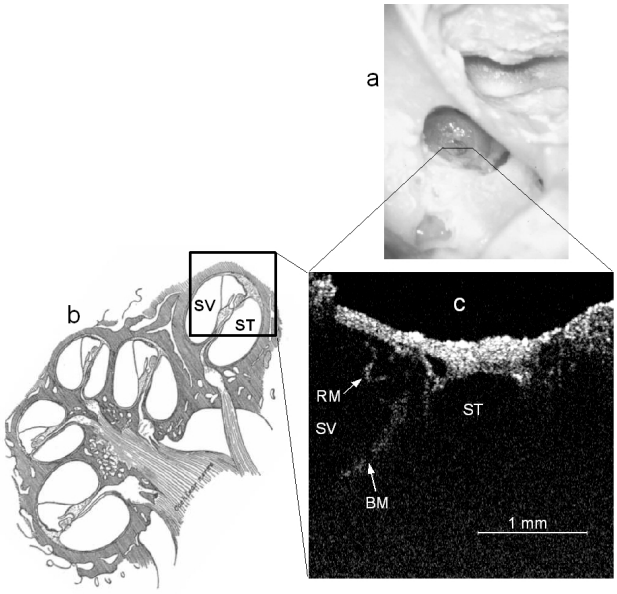

Fig. 4. Ex vivo measurement of the cochlear with the OCT operating microscope. a) Schematic image of the cochlear. b) Photo of the exposed cochlear in a fresh temporal bone. c) OCT scan of the lateral part of the exposed cochlear: besides the projections of the scalas some fine structures within the cochlear can be identified: the triangular cross section of the scala media with the Reissner membrane (SV = scala vestibule, ST = scala tympani, RM = Reissner membrane, BM = Basilar membrane).

4 Conclusions

Optical coherence tomography can be successfully integrated into a commercially available operation microscopy without compromising it's function. Hidden subsurface tissue structure can be visualized during surgery with a resolution of a few tens of a micrometer. Clinical applications of the new system may range from brain surgery [16], over ophthalmology [25] to ear surgery. OCT might contribute significantly to the safety of cochlear implant surgery.

Acknowledgements. This work was financially supported by Schleswig-Holstein (HWT 2004-12) and the Möller-Wedel GmbH.

References

1 D. Huang et al., in *Science* **254**, 1178, 1991
2 W. Drexler in *Invest Ophthalmol Vis Sci* **42**, 1993, 2001.

3 M. R. Hee et al., in *Arch Ophthalmol* **113**, 325, 1995.
4 M. R. Hee et al., in *Ophthalmology* **102**, 217, 1995.
5 C. A. Puliafito et al., in *J Biomed Opt* **9**, 47, 2004.
6 I. K. Jang et al., in *J Am Coll Cardiol* **39**, 604, 2002
7 B. E. Bouma et al. in *Gastrointestinal Endoscopy* **51**, 467, 2000
8 G. J. Tearney et al., in *Am J Gastroenterol* **92**, 1800, 1997
9 D. Daniltchenko et al. in *Radiologe* DOI 10.1007/s00117-005-1250-x, 2006;
10 E. V. Zagaynova et al., in *J Urol* **167**, 1492, 2002
11 J. M. Schmitt, M. J. Yadlowsky, R. F. Bonner, in *Dermatology* **191**, 93, 1995.
12 J. Welzel et al., in *Br J Dermatol* **150**, 220, 2004
13 B. W. Colston et al., in *Appl Opt* **37**, 3582, 1998
14 S. A.Boppart et al., in *Neurosurgery* **43**, 834, 1998
15 S. A. Boppart, in *Psychophysiology* **40**, 529, 2003
16 H. J. Böhringer et al., in *Lasers Surg Med* **38**, 588, 2006
17 M. Löning et al., in *Geburtsh Frauenheilk* **63**, 1158, 2003
18 G. J. Tearney et al., in *Science* **276**, 2037, 1997
19 T. Xie et al., in *Appl Opt* **42**, 6422, 2003
20 E. Lankenau et al., in *Proc. SPIE*, **5316,** 172, 2004
21 B.E .Bouma, and G. J. Tearney, *Handbook of Optical Coherence Tomography* Marcel Dekker, NewYork, 2002.
22 J. W. Goodmann, *Speckle Phenomena in Optics: Theory and Applications*, Roberts&Company, Greenwood Village, 2006.
23 Aschendorff et al., in *Otol Neurotol* **26**, 34, 2005
24 C. von Ilberg et al., in *J Otorhinolaryngol Relat Spec* **61**, 334, 1999
25 G. Geerling et al., in *Arch Ophthalmol* **123**, 253, 2005