The Journal of Laryngology & Otology (2009), ***123***, *1027–1030*.

doi:10.1017/S0022215109004770

Short Communication

Intra-operative application of optical coherence tomography with an operating microscope

T Just, E Lankenau*, G Hüttmann*, H W Pau

Abstract

Objective: To introduce the use of optical coherence tomography with an operating microscope for intra-operative evaluation of the human larynx.

Methods: A specially equipped operating microscope with integrated spectral domain optical coherence tomography apparatus was used during microlaryngoscopy.

Results: Technical improvements in optical coherence tomography equipment (e.g. pilot beam, variable focal distance, improved image quality and integration into an operating microscope) have enabled greater sensitivity and imaging speed and a non-contact approach. Spectral domain optical coherence tomography now enables a better correlation between optical coherence tomography images and histological findings. With this new technology, the precision of biopsy can be improved during microlaryngoscopy.

Conclusions: Use of this new optical coherence tomography technology, integrated into an operating microscope, enables the surgeon to define the biopsy site location and resection plane precisely, while the optical zoom of the operating microscope can be used over the complete range.

Key words: Optical Coherence Tomography; Larynx; Histology; Optical Biopsy; Vocal Cord

Introduction

Laryngeal cancer is one of the most common primary head and neck malignancies. Early detection relies on the identification of suspicious tissue, from which biopsies are taken to enable a definitive diagnosis. Better imaging technology is needed in order to improve the accuracy of intra-operative biopsies.

Over the last two decades, optical coherence tomography has steadily gained in importance and become one of the most promising new technologies for early detection of laryngeal cancer. This new technology has the potential for a great impact on laryngological practice, due to several unique properties and recent technical developments, as follows.

Firstly, optical coherence tomography enables an imaging depth of up to 2 mm, allowing identification of many intra-epithelial laryngeal lesions.[1,2] Secondly, high resolution optical coherence tomography (approximately 10 μm) enables visualisation of a cross-section of tissue and allows characterisation of normal laryngeal epithelium and of laryngeal lesions from different histogenetic origins. Thirdly, intra-operative application of optical coherence tomography enables rapid acquisition of high-quality images during surgery.[1–3] Fourthly, good correlations between optical coherence tomography images and conventional histology have been achieved, not only in normal tissue[4] but also in benign laryngeal lesions[1] and laryngeal cancer.[2]

Two of the drawbacks of optical coherence tomography encountered thus far are its slow imaging speed and the awkward handling of the probes used, which must be positioned in close vicinity to the tissue surface or in contact with it (this in turn may cause compression artefacts). The use of optical coherence tomography in ophthalmology has been revolutionised in recent years by a new approach to taking A-scans without moving parts, termed spectral domain optical coherence tomography. This system has important advantages compared with the commonly used time domain optical coherence tomography technique, with respect to imaging speed and sensitivity,[5] although its value for imaging strong-scattering, non-ophthalmological tissue is still under debate.[6]

In this study, we report our method of applying spectral domain optical coherence tomography technology during microlaryngoscopy. In contrast to previously published studies on optical coherence tomography devices, which mostly required special probes,[1–4] we used an operating microscope with an integrated optical coherence tomography system.[7–11] Our system incorporated technical improvements (e.g. pilot beam, variable focal distance and improved image quality) which represented important developments from the first reported systems combining optical coherence tomography technology with an operating microscope.[10–12]

The central part of our system was our recently developed spectral domain optical coherence tomography equipment, which employed a wavelength of 840 nm and provided improved resolution, sensitivity and imaging speed. The wavelength used was quite near to the visible range and therefore allowed the full optical path of the microscope to be used, without sacrificing image quality. Therefore, we were able to simply couple the optical

From the Department of Otorhinolaryngology, Head and Neck Surgery, University of Rostock, and the *Institute for Biomedical Optics, University of Lübeck, Germany.
Accepted for publication: 10 November 2008. First published online 26 February 2009.

coherence tomography equipment to the camera port of the microscope. This allowed the optical zoom function of the operating microscope to be used over the complete magnification range. An integrated pilot beam indicated to the surgeon the exact position of the scanning field.

The application of optical coherence tomography, incorporated within an operating microscope, to visualise laryngeal epithelia is briefly described below. This approach enabled significantly better correlation between optical coherence tomography images and macroscopic tissue structures. Our results indicated that our system of surgical microscopy with spectral domain optical coherence tomography at 830 nm was superior to current, microscope-based, time domain optical coherence tomography systems at 1300 nm, with respect to handling and image quality.

Materials and methods

System, imaging and image analysis

An operating microscope (Hi-R 1000; Möller Wedel GmbH, Wedel, Germany) was combined with a spectral domain optical coherence tomography system with a central wavelength of 840 nm, which allowed optical coherence tomography scans of any object in the centre of the microscopic field of vision (Figure 1a). Details of the integration of the microscope and the optical coherence tomography technology have been published elsewhere,[13] and are only briefly reviewed here.

The scan head of the optical coherence tomography device was coupled to the camera port of the microscope. Optical coherence tomography scanning was performed during normal visualisation of the tissue surface. Our device was based on a commercial optical coherence tomography system (Thorlabs, Newton, New Jersey, USA) but had increased output power and delivered a light intensity of 3 mW to the tissue. The lateral and longitudinal resolution were approximately 24 and 12 μm, respectively. The optical coherence tomography system was able to adjust automatically to imaging distances of between 230 and 290 mm, via computer-controlled adjustment of the reference arm length. Approximately 1 second was required to obtain an optical coherence tomography B-scan, consisting of 1000 single A-scans. A depth range of up to 3.5 mm could be visualised. Due to the light-scattering of most biological tissues, real measurement depths varied with tissue type, and reached 1–2 mm in the larynx. A green pilot beam indicated the optical coherence tomography scanning field. The system was CE (CE marking means french: Communauté Européenne = (german) „Europäische Gemeinschaft“ or Conformité Européenne, „Conformity with the European Union guidelines”) certified for intra-operative documentation of tissue structures.

Intra-operative application

The larynx was visualised using a laryngoscope. Photomicrographs were obtained whenever appropriate. Using the operating microscopy, a nominal working distance of between 224 and 280 mm was used for optical coherence tomography measurements (using a magnification of between ×4.0 and ×7.0). In the intra-operative setting, perpendicular optical coherence tomography sections through the true vocal folds were performed, and the images were stored digitally. Optical coherence tomography measurements were performed by the surgeon alone, without assistance. The process could be started manually, and images were displayed on a dedicated screen. A green pilot beam indicated the scanning field and enabled the surgeon to define the location of the biopsy and resection plane. Performing intra-operative optical coherence tomography scanning lengthened the normal operating time by 5 to 10 minutes.

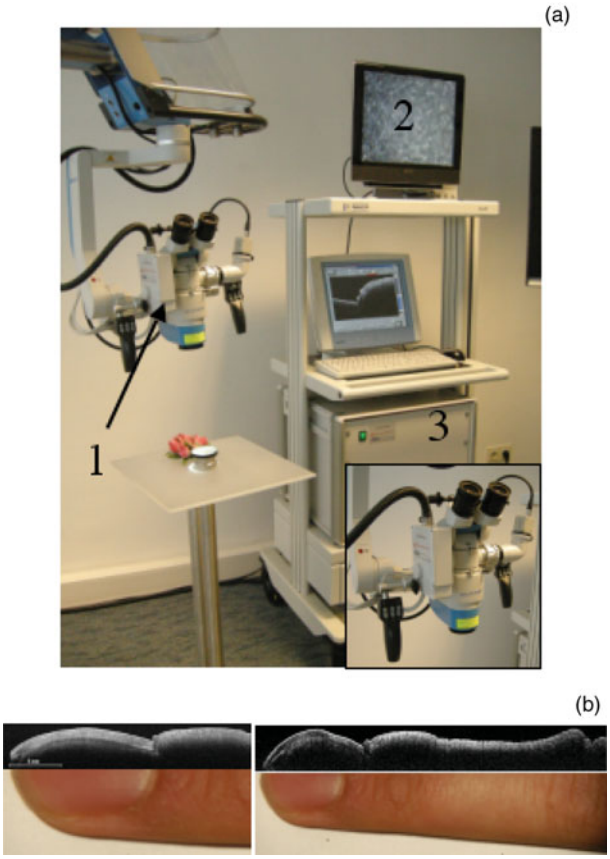

FIG. 1

(a) Operating microscope with integrated optical coherence tomography system. The scan head of the optical coherence tomography system (1; also shown in inset) is connected to the camera port; further optomechanical parts (including the reference arm and the spectrometer) are housed in a separate unit (3). Optical coherence tomography images are shown together with a video image on a special screen (2). (b) Optical coherence tomography images of a human finger, using different operating microscope magnifications.

Sterile covering of the microscope enabled the surgeon to also use the optical coherence tomography system during external laryngeal surgery when appropriate.

Results

Our optical coherence tomography system employed the zoom optics of the operating microscope, such that the field of view for optical coherence tomography imaging could be changed synchronously with the conventional image. This allowed imaging of quite different tissue fields, as shown in Figure 1(b). Focusing for optical coherence tomography was also done automatically according to the focus of the image the surgeon saw in the ocular. Despite the large imaging distance, the quality of the optical coherence tomography image was similar to that achieved when using a contact probe connected to the same optical coherence tomography device.

Our optical coherence tomography system imposed no restrictions on use of the operating microscope. Optical coherence tomography images were taken during normal procedures, after selecting magnification and focus, and

were displayed on a separate screen. The duration of operating time was approximately 5 minutes as a result.

During microlaryngoscopy, optical coherence tomography technology the basement membrane to be identified in all healthy subjects (Figure 2), and also in those with benign lesions of the larynx. A representative image of a case of Reinke's oedema is shown in Figure 3(a). In this patient, optical coherence tomography scanning made it possible to identify the typical low signal intensities of the gelatinous fluid (Figure 3a). Such scanning also enabled the surgeon to identify intra-operatively regions with remaining fluid chambers. In Figure 3(a), the well demarked area low signal intensity beneath the basal membrane within the lamina propria is consistent with oedema. After incision and suction of the oedema fluid, the remaining fluid chamber disappeared (Figure 3b). The corresponding histology, obtained by resection of the excessive epithelium, showed inflammation (Figure 3c).

Discussion

To date, most optical coherence tomography studies of the larynx have been conducted using a rigid or flexible probe.[1–3,14] This represents a substantial limitation when high precision is required in locating a biopsy site within the laryngeal epithelium. In addition, this approach is not always acceptable because of the difficulty in handling the optical coherence tomography probe while using surgical instruments. The importance of a non-contact application of optical coherence tomography technology was recognised in 2006.[2] One of the big advantages of optical coherence tomography over ultrasound is the avoidance of tissue contact during scanning.

The advent of fast spectral domain optical coherence tomography technology has renewed interest in coupling optical coherence tomography devices to the operating microscope. Here, we report our approach to optical coherence tomography scanning during microlaryngoscopy. When optical coherence tomography technology is integrated into an operating microscope,[10] tissue structures can be visualised and their extensions measured during surgery.[11] A new generation of optical coherence tomography devices based on the spectrally resolved detection of interference signals[15] has dramatically increased imaging speed.[5] These spectral domain optical coherence tomography devices have the potential to enable real-time, B-scan imaging and fast acquisition of three-dimensional volumes. Our newly developed optical coherence tomography operating microscope system addresses all the shortcomings of similar systems reported thus far,[11,12] namely: inferior image quality, complicated handling, restricted use of the surgical microscope, additional bulk, and unclear definition of the location of the B-scan.

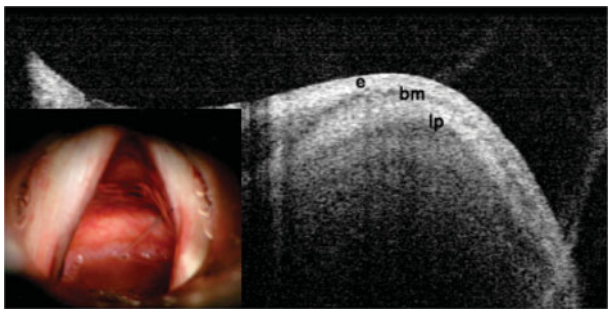

FIG. 2

Optical coherence tomography scan through a vertical cross-section of a healthy true vocal fold. Inset shows the clinical appearance of healthy true vocal folds. e = epithelium; bm = basal membrane; lp = lamina propria

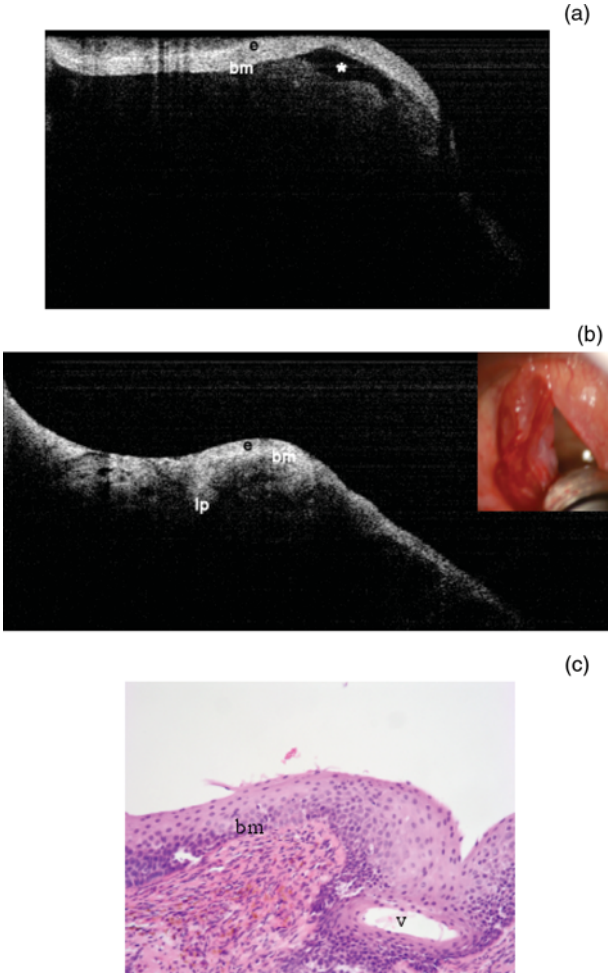

FIG. 3

(a) Optical coherence tomography scan of a case of Reinke's oedema. The well demarcated area low signal intensity beneath the basal membrane, within the lamina propria (*), is consistent with oedema. (b) Corresponding optical coherence tomography scan after incision and suction of the oedema fluid; inset shows the intraoperative situs after incision of the left vocal cord. (c) Corresponding photomicrograph reveals inflammation within the epithelium (H&E; ×40). e = epithelium; bm = basal membrane; lp = lamina propria; v = vesicle

It has been shown that optical coherence tomography scans can describe the microanatomy of the healthy larynx and of benign lesions.[1] Laryngeal cancer can be identified from the loss of basement membrane integrity.[2] This latter aspect of optical coherence tomography seems to have had the highest impact in the field of laryngology, as it enables early detection of microinvasive carcinoma. With identification and localisation of the focal basement membrane damage seen in microinvasive carcinoma, it should be possible to improve the accuracy of biopsies during diagnostic microlaryngoscopy. We expect that our system will allow us to benefit from this advantage.

The interpretation of optical coherence tomography images obtained intra-operatively is always dependent on the viewer's experience, and scans should be compared with conventional histology in cooperation with a pathologist. The accuracy of interpretation of optical coherence tomography images is subject to a learning curve similar

to that for interpretation of ultrasound, computed tomography and magnetic resonance imaging scans.

Improvement in optical coherence tomography technology is an ongoing process. Our future research will focus on the provision of optical coherence tomography images to surgeons as they look through the microscope, and on the development of three-dimensional, real-time optical coherence tomography scanning. Real-time optical coherence tomography should provide instantaneous scanning information on the larynx. This will enable the surgeon to precisely identify the border of the lesion and also to obtain information during surgery. Optical coherence tomography guided resection may become feasible.

The method presented in this paper will be explored in a further study in patients with dysplastic, precancerous and malignant lesions of the larynx. The aim of this future, prospective study will be to assess the diagnostic sensitivity, specificity and accuracy of optical coherence tomography equipment coupled with an operating microscope, compared with data obtained by optical coherence tomography devices using special probes.

Conclusions

Optical coherence tomography scanning using equipment coupled with an operating microscope is a non-contact procedure which has important advantages over optical coherence tomography scanning conducted via special probes, in that the optical zoom of the operating microscope can be used in its complete range during surgery. In our experience of our optical coherence tomography system, the technical problems hindering clinical use were largely resolved. Our optical coherence tomography system was easy to handle intra-operatively, and no assistance was required for optical coherence tomography scanning.

References

1 Wong BJ, Jackson RP, Guo S, Ridgway JM, Mahmood U, Su J *et al*. In vivo optical coherence tomography of the human larynx: normative and benign pathology in 82 patients. *Laryngoscope* 2005;**115**:1904–11

2 Armstrong WB, Ridgway JM, Vokes DE, Guo S, Perez J, Jackson RP *et al*. Optical coherence tomography of laryngeal cancer. *Laryngoscope* 2006;**116**:1107–13

3 Kraft M, Luerssen K, Lubatschowski H, Glanz H, Arens C. Technique of optical coherence tomography of the larynx during microlaryngoscopy. *Laryngoscope* 2007;**117**:950–2

4 Bibas AG, Podoleanu AG, Cucu RG, Bonmarin M, Dobre GM, Ward VM *et al*. 3-D optical coherence tomography of the laryngeal mucosa. *Clin Otolaryngol Allied Sci* 2004;**29**: 713–20

5 Leitgeb RA, Hitzenberger CK, Fercher AF. Performance of Fourier domain vs. time domain optical coherence tomography. *Opt Express* 2003;**11**:889–94

6 Liu B, Brezinski ME. Theoretical and practical considerations on detection performance of time domain, Fourier domain, and swept source optical coherence tomography. *J Biomed Opt* 2007;**12**(4):044007 (doi: 10.1117/1.2753410)

7 Just T, Lankenau E, Hüttman G, Pau HW. Optical coherence tomography as a guide for cochlear implant surgery? In: Wong BJ, Ilgner JFR, eds. *SPIE Photonics West*. San Jose: Bellingham, 2008

8 Pau HW, Lankenau E, Just T, Behrend D, Hüttmann G. Optical coherence tomography as an orientation guide in cochlear implant surgery? *Acta Otolaryngol* 2007;**127**: 907–13

9 Pau HW, Lankenau E, Just T, Hüttmann G. Imaging of cochlear structures by optical coherence tomography (OCT). Temporal bone experiments for an OCT-guided cochleostomy technique [in German]. *Laryngorhinootologie* 2008;**87**:641–6

10 Geerling G, Muller M, Winter C, Hoerauf H, Oelckers S, Laqua H *et al*. Intraoperative 2-dimensional optical coherence tomography as a new tool for anterior segment surgery. *Arch Ophthalmol* 2005;**123**:253–7

11 Heermann R, Hauger C, Issing PR, Lenarz T. Application of optical coherence tomography (OCT) in middle ear surgery [in German]. *Laryngorhinootologie* 2002;**81**:400–5

12 Vokes DE, Jackson R, Guo S, Perez JA, Su J, Ridgway JM *et al*. Optical coherence tomography-enhanced microlaryngoscopy: preliminary report of a noncontact optical coherence tomography system integrated with a surgical microscope. *Ann Otol Rhinol Laryngol* 2008;**117**:538–47

13 Lankenau E, Klinger D, Winter C, Malik A, Müller HH, Oelckers S *et al*. Combining optical coherence tomography (OCT) with an operating microscope. In: Buzug TM, Holz D, Weber S, Bongartz J, Kohl-Bareis M, Hartmann U, eds. *Advances in Medical Engineering*. Berlin, Heidelberg: Springer, 2007:343–8

14 Sommer K, Lankenau E, Thorns C, Fedder C, Hüttman G, Wollenberg B. Optical coherence tomography – a new non-invasive high resolution imaging for cancer and precancerous lesions of the upper aerodigestive tract. In: Papaspyrou S, ed. *5th European Congress of Oto-Rhino-Laryngology Head and Neck Surgery*, Bologna: Medimond, 2004:401–4

15 Häusler G, Lindner MW. "Coherence radar" and "spectral radar" – new tools for dermatological diagnosis. *J Biomed Opt* 1998;**3**:21–31

Address for correspondence:
Dr Tino Just,
Department of Otorhinolaryngology,
Head and Neck Surgery,
University of Rostock,
Doberaner Strasse 137–139
D-18057 Rostock, Germany.

Fax: +49 381 494 8302
E-mail: tino.just@med.uni-rostock.de

Dr T Just takes responsibility for the integrity of the content of the paper.
Competing interests: None declared